

03-3514



805 Pamplico Hwy, Ste B-210; PO Box 6166
Florence, South Carolina 29502
Ph. 843-664-4314 Fax 843-664-4340

Physician(s): LOCAL DOCTOR MD

Patient: **PATIENT, FEMALE**
222 ANYPLACE ST
FLORENCE, SC 29501
Birthdate: **05/05/1955** Age: 52 Sex: F

Location: **LOCAL HOSPITAL**
Chart #: LH-1234 Room: IN

Collection Date: 06/25/2007
Received Date: 06/25/2007

SURGICAL PATHOLOGY REPORT
Case Number: **S2006-002025**

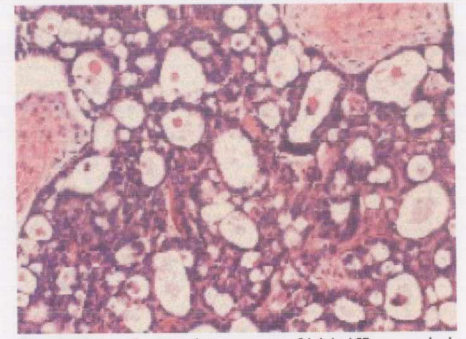


Clinical Information:
Fibroid uterus

Specimen Source:
UTERUS, AND CERVIX

MICROSCOPIC DIAGNOSIS:

Uterus, hysterectomy:
Cervix: No pathologic abnormality.
Endometrium: Secretory phase.
Myometrium: Leiomyoma.
Serosal mass: Female adnexal tumor of Wolffian origin
(FATWO). See comment.



Female adnexal tumor of Wolffian origin

KLR/ca 6-26-07

Comment:

This is a very unusual tumor measuring approximately 18.0 cm. in greatest dimension and located along the broad ligament. The immunohistochemical stain profile is strongly supportive of a diagnosis of female adnexal tumor of Wolffian origin.

Immunohistochemical stain profile results:

- Inhibin - Negative
- Cytokeratin - Positive
- Calretinin - Weakly positive
- PR - Negative
- CD-10 - Positive

INTRADEPARTMENTAL CONSULTATION(S): Dennison B. Robey, M.D./Pathologist
Tarek M. Bishara, M.D./Pathologist; William V. Farnsworth, M.D./Pathologist

Electronically signed by
KENNETH L RIES, M.D./PATHOLOGIST
(Case signed 06/27/2007)

03-3514



805 Pamplico Hwy, Ste B-210; PO Box 6166
Florence, South Carolina 29502
Ph. 843-664-4314 Fax 843-664-4340

Physician(s): LOCAL DOCTOR MD

Patient: PATIENT, FEMALE
222 ANYPLACE ST
FLORENCE, SC 29501
Birthdate: 05/05/1955 Age: 52 Sex: F

Location: LOCAL HOSPITAL
Chart #: LH-1234 **Room:** IN

Collection Date: 06/25/2007
Received Date: 06/25/2007

SURGICAL PATHOLOGY REPORT
Case Number: S2006-002025



Gross Description:

Labeled: Female Patient; Uterus, cervix
Received: in formalin: open uterus with attached cervix and multiple free-floating portions of tumor tissue
External Appearance: pink-tan, roughened
Weight: 180 grams
Measurement: 14.1 x 7.8 x 4.1 cm
Endocervix: up to 2.2
Endometrium: up to 0.2 cm.
Myometrium: up to 1.8 cm.
Tumor Nodules: multiple: intramural and free-floating, the largest tumor measures 18.0 x 17.0 x 5.0 cm. and sectioning reveals white and pink-tan whorled tissue
Section Summary: eleven cassettes: A, cervix, 2s; B, endometrium and body, 2s; C - K, tumor nodules, 11s
TH/ca 6-25-07