



805 Pamlico Hwy, Ste B-210, PO Box 6166
 Florence, South Carolina 29502
 Ph. 843-664-4314 Fax 843-664-4340

SURGICAL PATHOLOGY REPORT

Physician(s): DENNISON B ROBEY MD

Patient: **TEST, PATIENT**
 111 SOMEWHERE ST
 SOMEPLACE SC 11111
 Birthdate: 02 02 1922 Age: 81 Sex: M

Location: **THE UROLOGY CLINIC**
 Chart #: 12345
 Room:

Case Accession No.: **S03-1000**

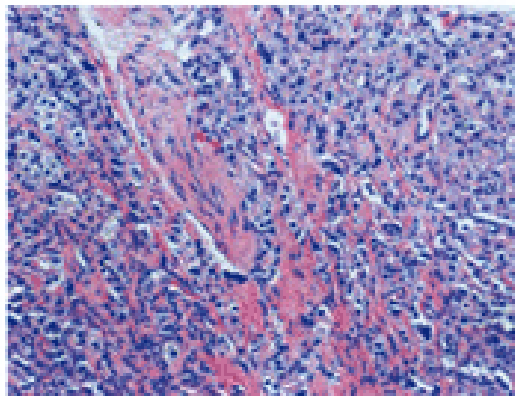
Date of Procedure: 05 30 2003
 Date Received: 05 30 2003

Clinical Information:

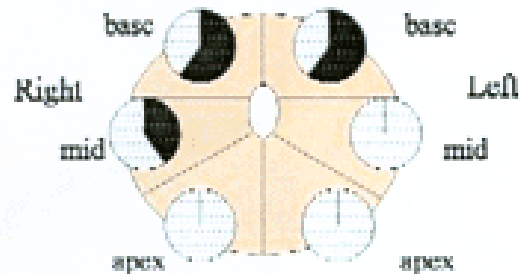
1. PSA 23.5, fam hx of prostate Ca

Specimen Source:

1. Source, PROSTATE, RIGHT APEX
2. Source, PROSTATE, RIGHT MID
3. Source, PROSTATE, RIGHT BASE
4. Source, PROSTATE, LEFT APEX
5. Source, PROSTATE, LEFT MID
6. Source, PROSTATE, LEFT BASE



Prostatic adenocarcinoma



Shaded area = % malignant

MICROSCOPIC DIAGNOSIS:

1. Prostate, right apex, needle biopsies: Severe acute and chronic inflammation.
2. Prostate, right mid, needle biopsies: Adenocarcinoma, Gleason's score 8 (4 + 4).
Tumor involves approximately 40% of submitted tissue.
3. Prostate, right base, needle biopsy: Adenocarcinoma, Gleason's score 9 (5 + 4).
Tumor involves approximately 60% of submitted tissue.
4. Prostate, left apex, needle biopsies: Severe acute and chronic inflammation.
5. Prostate, left mid, needle biopsies: Severe acute and chronic inflammation.
6. Prostate, left base, needle biopsy: Adenocarcinoma, Gleason's score 9 (5 + 4).

1 of 2 on 09-12-2003 at 13:34 for S03-1000 TEST, PATIENT WP254748 WP254749

Original copy