

03-3514



805 Pamplico Hwy, Ste B-210; PO Box 6166  
Florence, South Carolina 29502  
Ph. 843-664-4314 Fax 843-664-4340

Physician(s): LOCAL DOCTOR MD

Patient: PATIENT, FEMALE  
222 ANYPLACE ST  
FLORENCE, SC 29501  
Birthdate: 05/05/1955 Age: 50 Sex: F

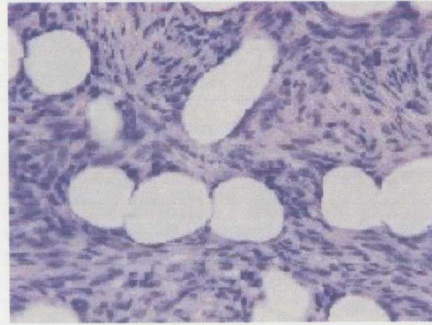
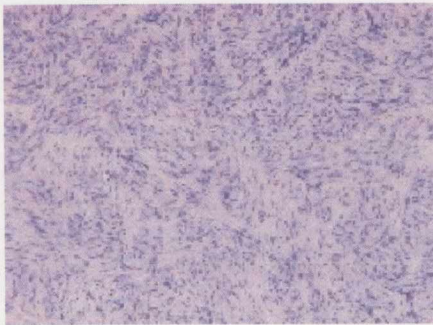
Location: LOCAL OFFICE  
Chart #: 33221 Room:

Collection Date: 04/19/2006  
Received Date: 04/19/2006

**SURGICAL PATHOLOGY REPORT**  
Case Number: S2006-002006



Specimen Source:  
LESION, RIGHT UPPER CHEST



**MICROSCOPIC DIAGNOSIS:**  
Skin, right upper chest, excision: Dermatofibrosarcoma protuberans. See comment.

KLR/ca 4-19-06

**Comment:**

Dermatofibrosarcoma protuberans (DFSP) is a low grade sarcoma with propensity to recur locally and demonstrate occasional distant metastases. We strongly suggest a wide local excision as the surgical margin is positive.

INTRADEPARTMENTAL CONSULTATION: Dennison B. Robey, M.D./Pathologist

KENNETH L RIES, M.D./Pathologist  
(Case signed 01/09/2007)